



ALKA HOSPITAL

Plastic & Microvascular Surgery Centre
42/17 A, Church Lane, Allahabad. Ph.: 0532-2465464, 2465494

Date: 27.10.2018

Estimate

Mr. Dhananjay Mishra Age 25Yr/M S/o Mr. Vijay Kant Mishra R/o Village & Post Basheerpur Pratapgarh (U.P.) He is a follow up case of accidental crush compound injury right lower leg with flap reconstruction .

(1). Hospital Exp.: Admission Fee ,Operation, Anesthesia,

Dressing, Care Fee, Monitor etc For

10Days

Rs.110000/- Approximate

(2). Medicine Exp.: Par Day Rs.30000 /-

Approximate For 10 Days

Rs.300000/- Approximate

Total Rs. 410000/-Approximate

1+2 Total Rs.410000 /- Approximate Estimated.

Dr. D. C. Srivastava
Dr. D.C. Srivastava

Regd. No. 25059

Medical Counsel

Lucknow



42/17 A, Church Lane, Allahabad Ph.: 2465464, 2465494

ALKA HOSPITAL

Plastic & Microvascular Surgery Centre

Date: 09.07.2017

Estimat

Mr. Dhananjay Mishra 25 Yr/M S/o Mr. Vijay Kant Mishra R/o Vill & Post Basher Pur Pratapgarh (U.P.) He has been admitted in this hospital on 14.06.2017 in emergency case of crush compound injury right lower leg.

(1) He has spent about Rs. 860000/- (Eight lakh sixty thousand till date 09.07.2017 on Admissin, Operation anaesthesia Hospital stay Medicine etc.

(2) Expected expenditure is as below for
Hospital Exp.: Hospital stay, Dressing,
Monitor, Care Fee, etc For

14 Days

Rs. 100000/- Approximate

Medicine Exp.: Per Day Rs.30000/-

Approximate For 14 Days

Rs. 420000/- Approximate

Rs. 520000/- Approximate

1+2 = Total Rs. 1380000/- Approximate Estimate

Dr. D. C. Srivastava



22.5.18 Bal. 200 x-ray
10.5.18 Bal. 300 Dressing

D.O.P.R



ALKA HOSPITAL
Plastic & Microvascular Surgery Centre
42/17 A, Church Lane, Allahabad. Ph.: 2465464, 2465494

DISCHARGE CARD

Wt

Name Mr Dhonajay Age/Sex 28. year
Surgeon/Physician/IC Dr De Ananta va. Ms. Mrs. Madh. Kumar
Diagnosis func. ch. wound sup. @ lower lip E. Exposed
D.O.A. 28/3/18 D.O.P.R on 2/4/18 Buehal
Date of Operation 27/8/18 Result Surgeon

CLINICAL HISTORY & INVESTIGATION

Reports attached with

TREATMENT GIVEN

opt
I

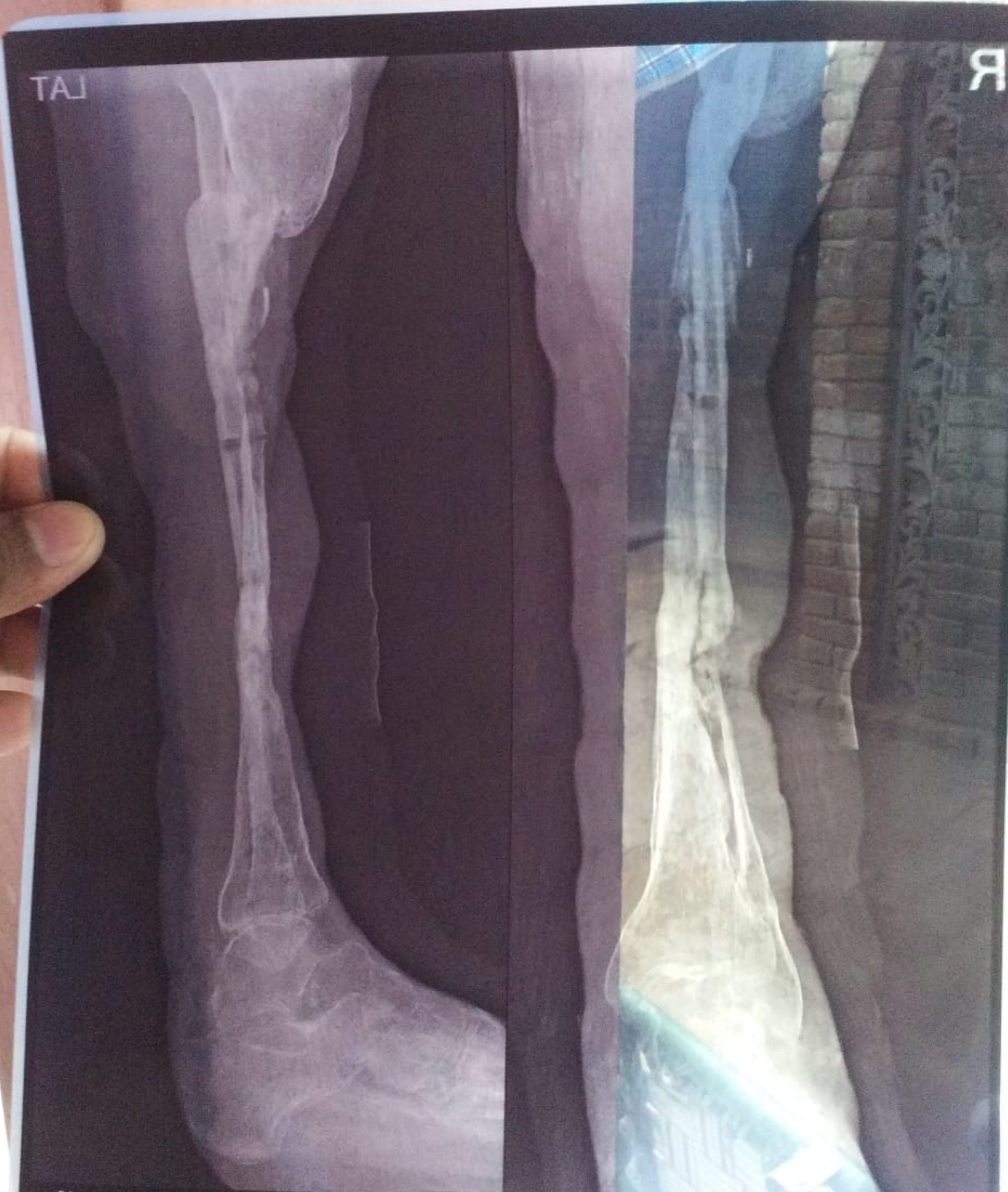Wound sutured on 27/3/18
wound sutured on 27/3/18

18/4/18 Dr. De Ananta va. Ms. Mrs. Madh. Kumar
to consult me 25/6/18

R

LAT

DMANANJAY MISHRA ZYIM DR DC SRIVASTAVA MS MCH 2425
ALKA HOSPITAL, CHURCH LANE, ALLAHABAD
TIB-FIB AP/LAT 17-MAY-19



TREATMENT ADVISED AND FOLLOWUP:
2/4/18 2018

01/06/18
 - Dressing done
 - come for dressing
 after 1 week

any more
 Dr. Mahyuni 3000000

→ tas kofstar 500 we 1200

→ tas herox 500 1000

→ tas hulu 500 1000

→ tas henn 600 1300

→ tas henyun 200 we 1200

→ ~~tas~~ tas pentul 400 1300

→ Cap Merdun 500 1300

22/5/18
 induct
 record
 to 20/5/18

→ tas hulu 500 1000

29/5/18 → tas henn 1000

→ tas henn 2000-1000
 = 1000

Note: further treatment by
 consultant doctor John

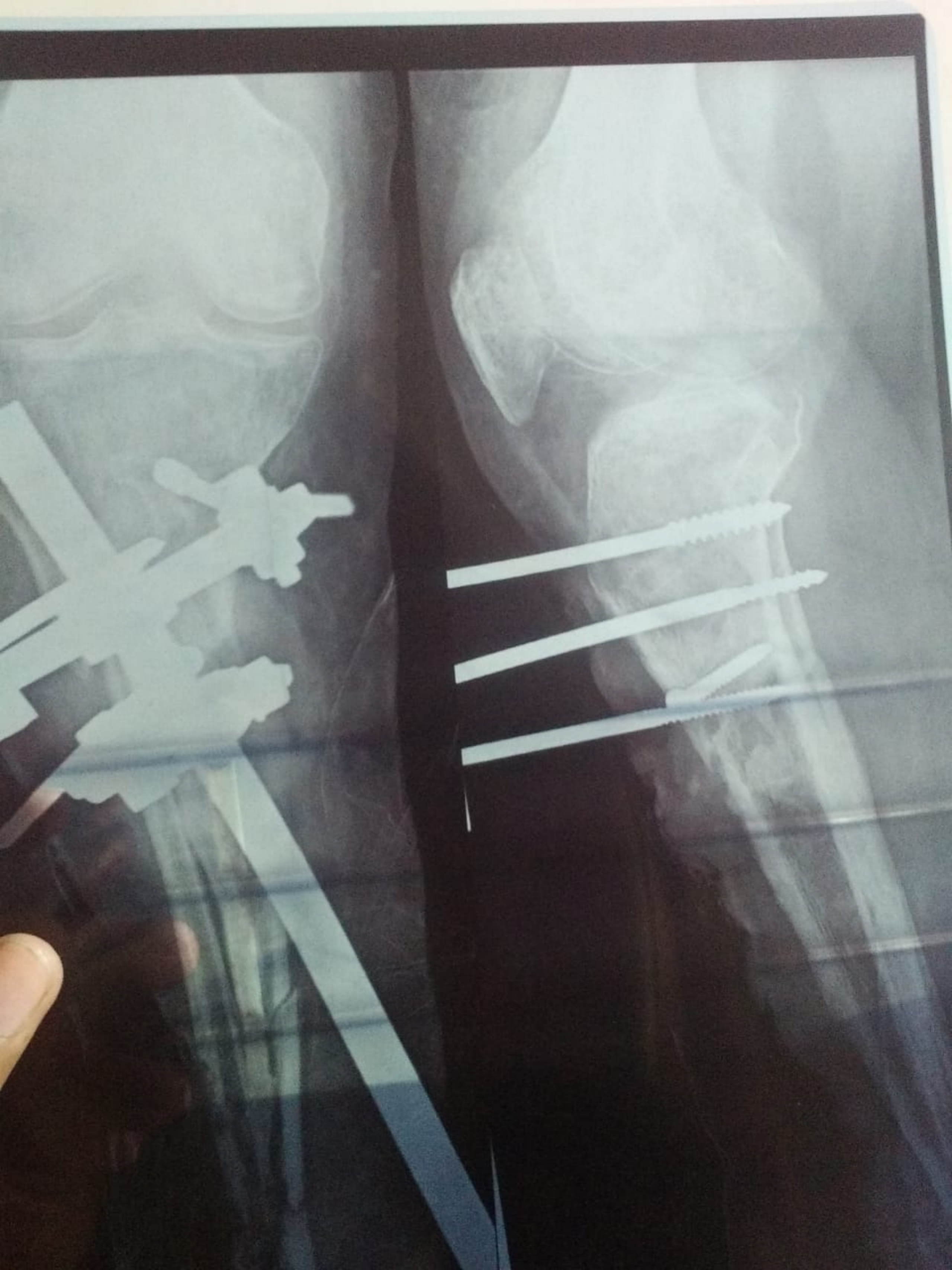8/4/18 Inj. Dany
 cannot be
 recovery 13/4/18

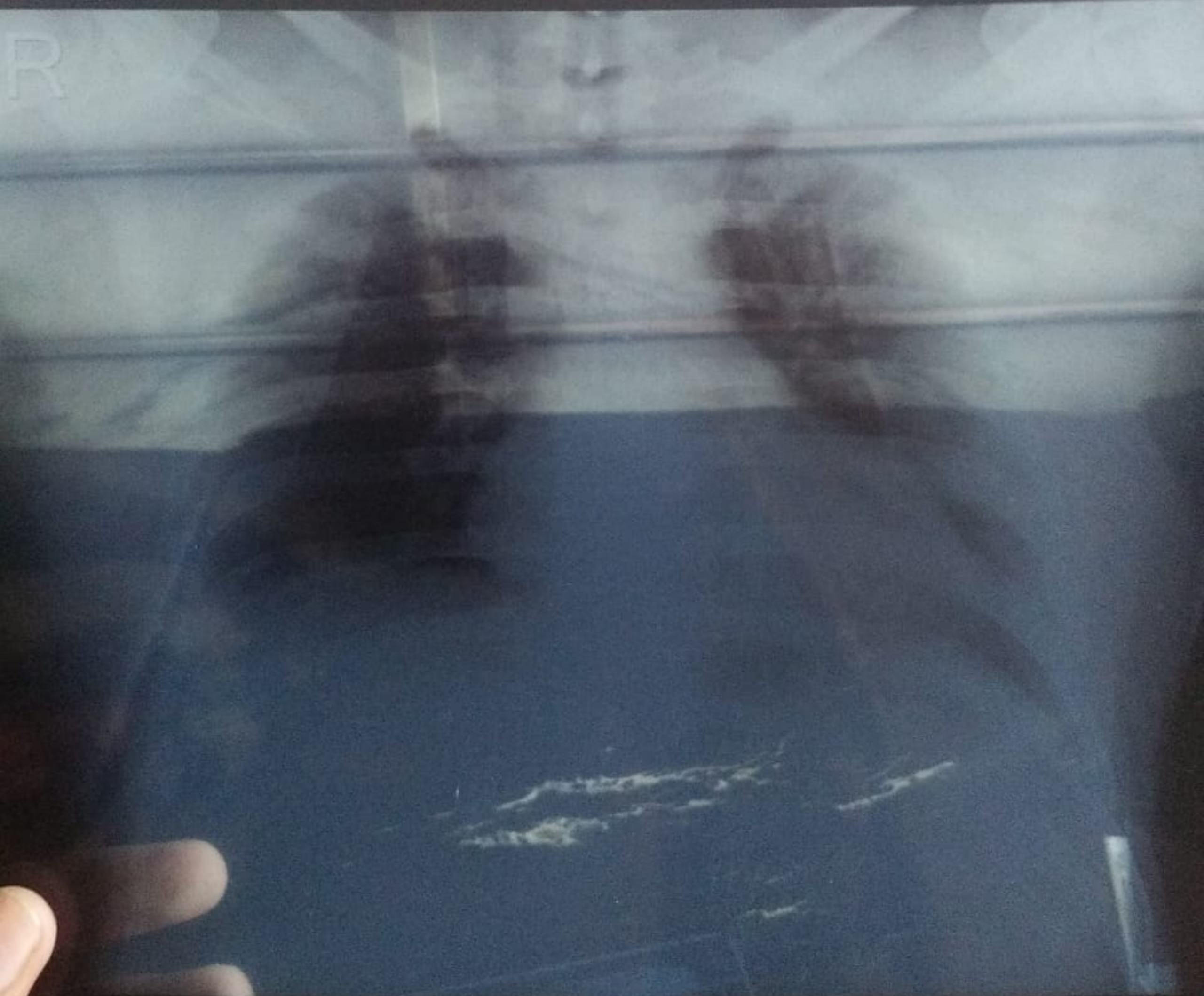
18/4/18 Inj. Dany
 cannot be
 recovery 21/4/18

23/4/18 Inj. Dany
 cannot be
 recovery 28/4/18

2/5/18 Inj. Dany
 cannot be
 recovery 7/5/18

08/05/18
 Dressing done, CST
 (come for
 dressing after 5
 days)

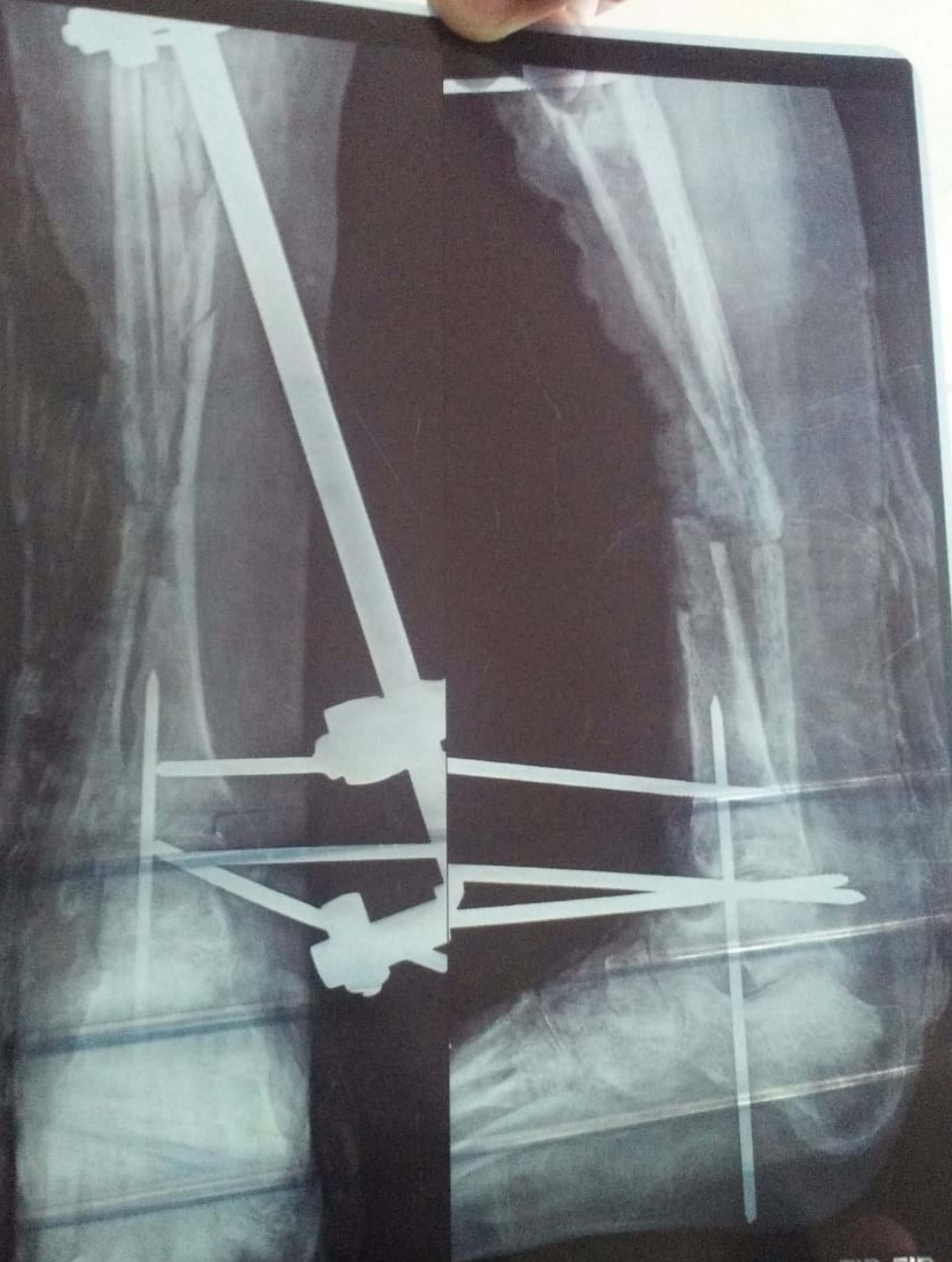



R

DHANANJAY MISHRA 25Y/M DR DC SRIVASTAV MS MCH 188 CHEST AP 09-Nov-1
ALKA HOSPITAL, CHURCH LANE, ALLAHABAD

R



DHANANJAY MISHRA 25Y/M DR DC SRIVASTAV MS MCH 188
ALKA HOSPITAL, CHURCH LANE, ALLAHABAD

TIB-FIB

R

PLAT

DHANANJAY MISHRA 25Y/M DR DC SRIVASTAV MS MCH 188
ALKA HOSPITAL, CHURCH LANE, ALLAHABAD

TIB-FIB

Handwritten text at the top of the page, possibly a title or header, which is difficult to read due to the image quality and angle.

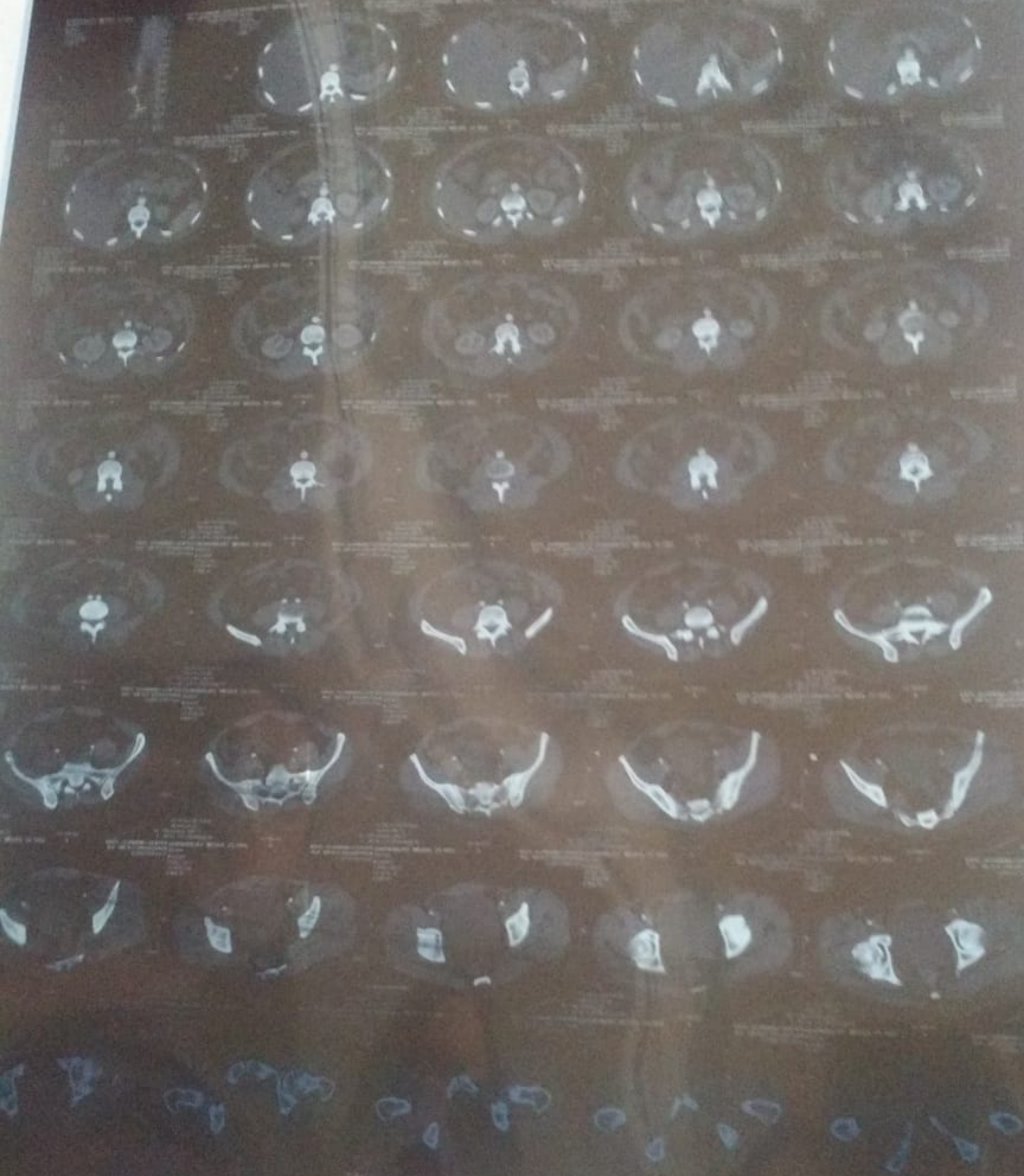A grid of 10 columns and 10 rows of small, light-colored circles on a dark background. The circles are arranged in a regular pattern, with some faint markings or text visible in the lower portion of the grid.

Handwritten text at the bottom of the page, possibly a signature or footer, which is partially obscured by a hand holding a white object.

KRITI SCAN CENTRE, LOWTHER ROAD, ALLAHABAD, PIN 2256805, 2256266



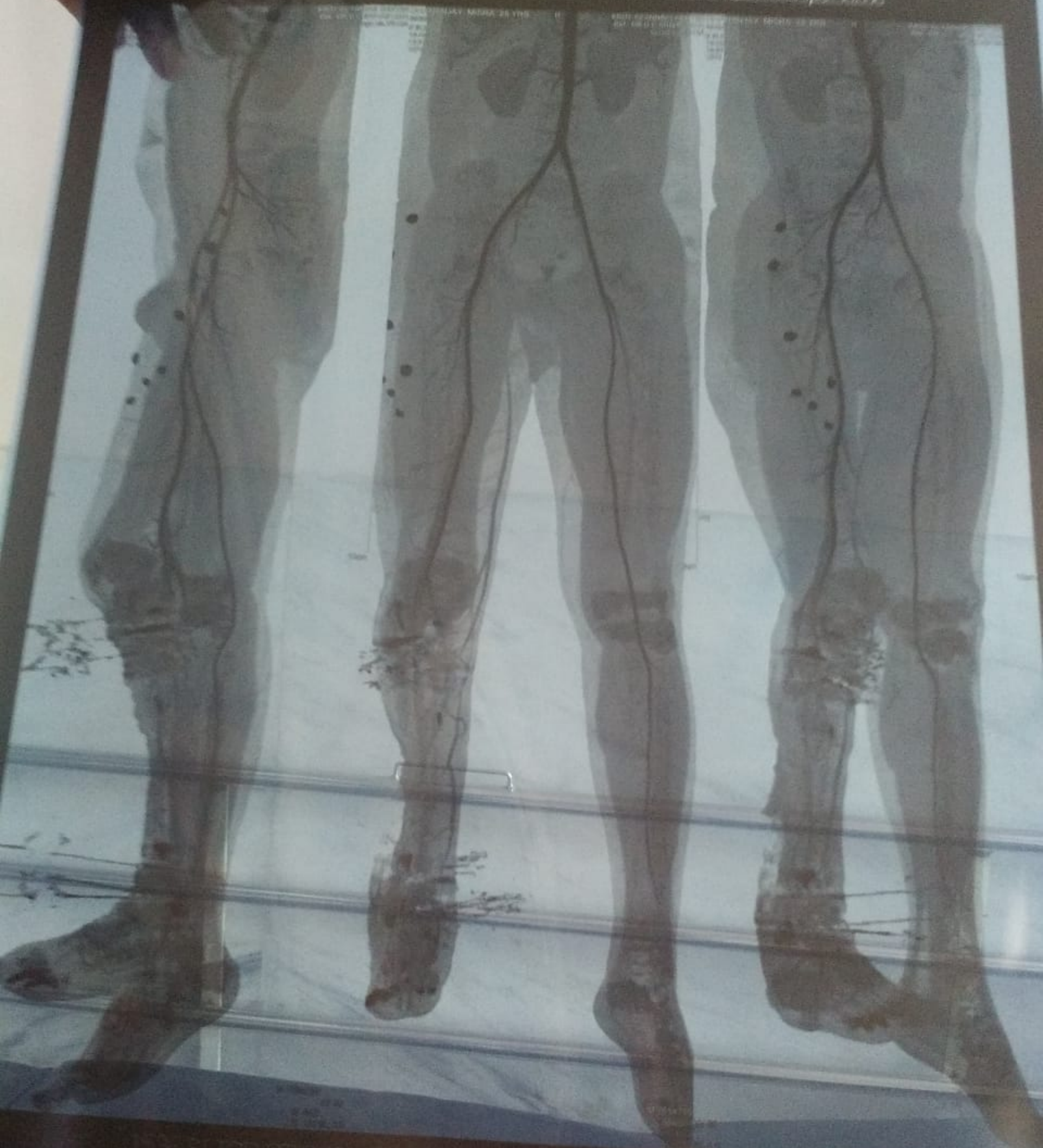KI CT SCAN CENTRE, LOWTHER ROAD, ALLAHABAD, PH. 202005, 202003



1530 SLICE CT S

1.0 TESLA MRI, DIGITAL XRAY, DEXA BMD

RITI SCAN CENTRE, LOWTHER ROAD, ALLAHABAD, PH. 2251805, 2251806



TESLA MRI, DIGITAL XR

KRITI SCAN CENTRE, LOWTHER ROAD, ALLAHABAD, PH: 2222222222

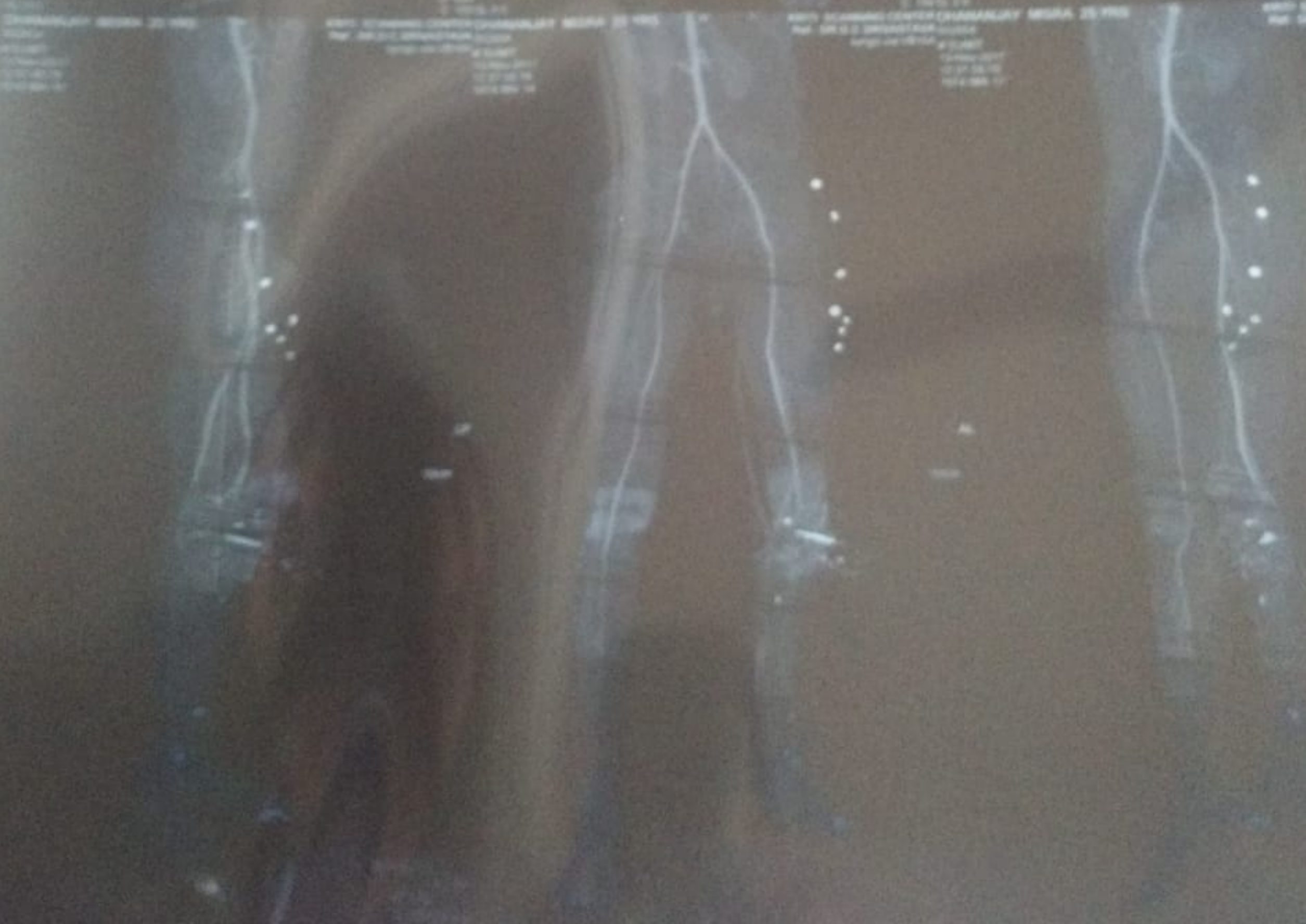
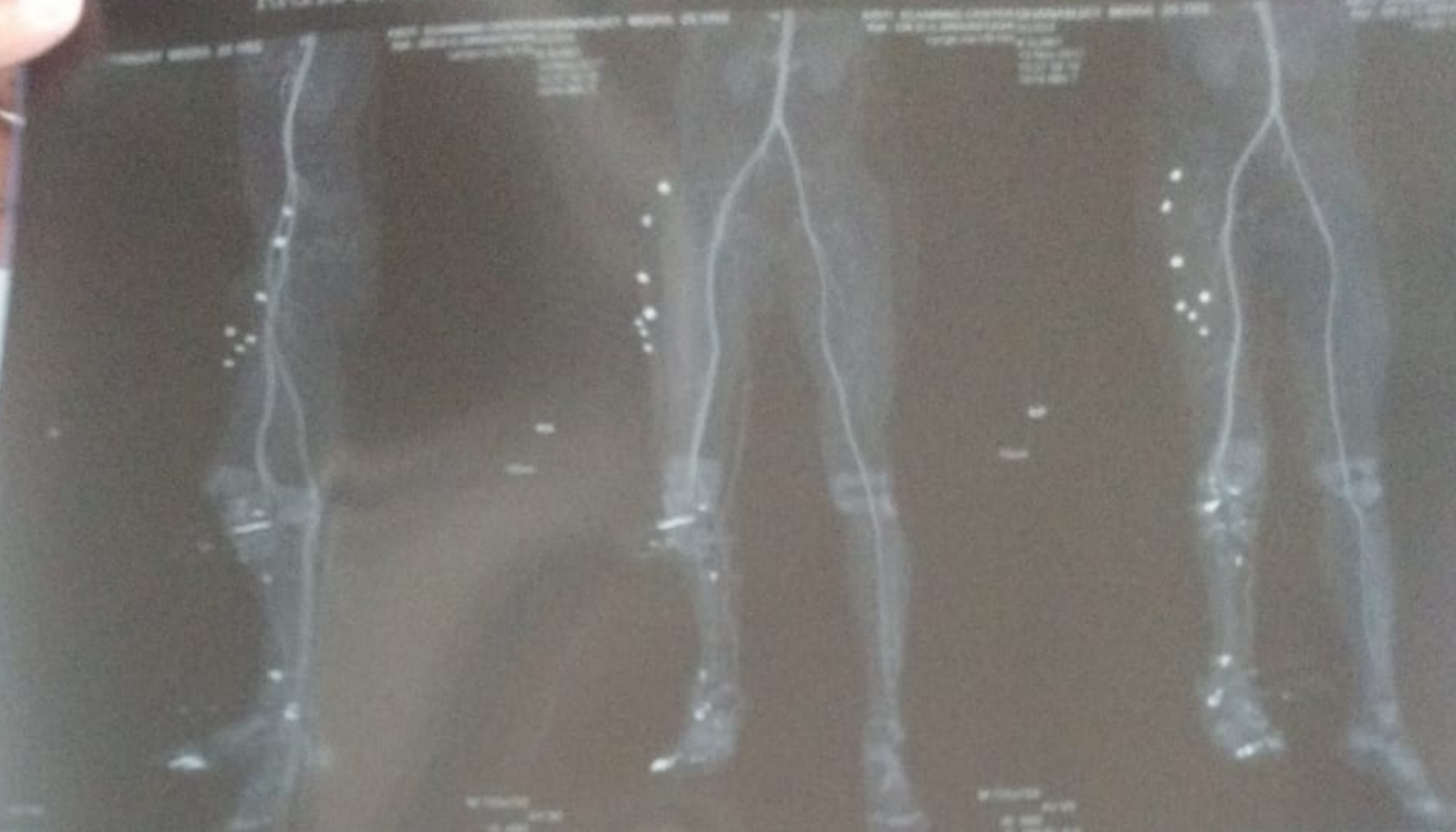
CT SCAN, 3.0 TESLA MRI, DIGITAL XRAY, TECH. P...

SCAN CENTRE, LOWTHER ROAD, ALLAHABAD. PH. 2256805, 2256266



CT SCAN, 3.0 TESLA MRI, DIGITAL XRAY, DEXA BMD





Kritiscanning Centre (P) Ltd.

OPEN TYPE 3.0 TESLA M.R.I., MULTISLICE (6 Slice) SPIRAL C.T. SCAN, COLOUR DOPPLER, USG, 2D ECHO, DIRECT DIGITAL RADIOGRAPHY, DEXA BMD, DIGITAL (OPG), DIGITAL MAMMOGRAPHY

59/18-E Lowther Raod, (In front of Medical College), Allahabad
Regd. Off. : 55-B Lowther Raod, Allahabad-211002

E-mail: kritiscan@gmail.com Website: kritiscanningcentre.com

Phones- Reception: 0532-2256805, 2256266 - CT Scan: 2256151 - MRI: 2256100

Name	: Dhananjay Mishra	852854
Age/Sex	: 25 years/ male	

Impression: Ununited compound comminuted fractures of tibia with external fixator and an intramedullary nail at distal shaft of tibia through the ankle joint stabilising the external fixator.

Extensive Superficial and deep soft tissue loss seen in the anterior part of the right distal leg and anterior compartment with blebs of air noted.

Possible collection with air fluid level anteromedially at the upper leg measuring 3 x 1.5 cm

Right likely long-standing occlusion at level of distal popliteal artery with collateral vessels leading to reformation of single dominant artery in the lower leg 5 cm distally -common peroneal artery which distally gives rise to the posterior tibial artery. Right Anterior tibial artery and dorsalis pedis arteries are not visualised.

On the left, Hypoplastic anterior tibial artery. Single dominant artery in the left lower leg which is likely the common peroneal artery. At the level of ankle, the common peroneal artery divides into dorsalis pedis and posterior tibial arteries.

Adv: Clinical Correlation.

DR. V.K.AGARWAL, MD

DR. KUSHAGRA AGRAWAL; MD

DR. RACHIT SIDANA; DNB

DR. UDBHAV MAHESHWARI; DMRD

DR. RAVINDRA KUMAR BIND; MD

DR. SEEMA PANDEY; MD



Kriti Scanning Centre (P) Ltd.

OPEN TYPE 3.0 TESLA M.R.I., MULTISLICE (6 Slice) SPIRAL C.T. SCAN, COLOUR DOPPLER, USG, 2D ECHO, DIRECT DIGITAL RADIOGRAPHY, DEXA BMD, DIGITAL (OPG), DIGITAL MAMMOGRAPHY

59/18-E Lowther Raod, (In front of Medical College), Allahabad
Regd. Off. : 55-B Lowther Raod, Allahabad-211002

E-mail: kritiscan@gmail.com Website: kritiscanningcentre.com

Phones- Reception: 0532-2256805, 2256266 • CT Scan: 2256151 • MRI: 2256100

Name	: Dhananjay Mishra	852854
Age/Sex	: 25 years/ male	
Date	: 14 November 2017	
Referred by	: Dr D C Srivastava MS	

CT Lower Limb Angiography

Report:

Plain axial scans (prior to angiography) were obtained in the region of interest. Angiography study was performed on a multidetector (1536 slice) SOMATOME FORCE CT scanner using bolus tracking technique. Approx 90 ml nonionic iodinated contrast was injected intravenously into an arm vein by pressure injector at rate of 4 ml/sec. Axial contiguous sections were taken from the above the level of origin of celiac trunk to aortic bifurcation. Post processing multiplanar reconstructions were performed in coronal and sagittal planes and 3-D reconstructions with MIP technique. Study reveals:

Findings:

BONES: Normal on the left. On the right,

- ✘ Ununited compound comminuted fractures of tibia with external fixator and an intramedullary nail at distal shaft of tibia through the ankle joint stabilising the external fixator.
- ✘ Extensive Superficial and deep soft tissue loss seen in the anterior part of the distal leg and anterior compartment with blebs of air noted. Significant atrophy of muscles in the leg more so distally. Mild atrophy in thigh
- ✘ Possible collection with air fluid level anteromedially at the upper leg measuring 3 x 1.5 cm
- ✘ Non-union of fractures at proximal shaft of fibula and distal shaft of fibula
- ✘ Patchy osteopenia in the bones of the right knee and lower leg likely due to disuse. amputation of big toe noted

SUPRARENAL ABDOMINAL AORTA: Normal to extent seen

CELIAC AND MESENTERIC ARTERIES: Replaced right hepatic artery from superior mesenteric artery

RENAL ARTERIES: Dominant Accessory left renal artery

INFRARENAL ABDOMINAL AORTA: Normal.

AORTIC BIFURCATION: Normal.

Kriti Scanning Centre (P) Ltd.

OPEN TYPE 3.0 TESLA M.R.I., MULTISLICE (6 Slice) SPIRAL C.T. SCAN, COLOUR DOPPLER, USG, 2D ECHO, DIRECT DIGITAL RADIOGRAPHY, DEXA BMD, DIGITAL (OPG), DIGITAL MAMOGRAPHY

59/18-E Lowther Road, (In front of Medical College), Allahabad
Regd. Off. : 55-B Lowther Road, Allahabad-211002

E-mail: kritiscan@gmail.com Website: kritiscanningcentre.com

Phones- Reception: 0532-2256805, 2256266 • CT Scan: 2256151 • MRI: 2256100

Name	: Dhananjay Mishra	852854
Age/Sex	: 25 years/ male	

RIGHT COMMON ILIAC ARTERY: Normal.
RIGHT EXTERNAL ILIAC ARTERY: Normal.
RIGHT INTERNAL ILIAC ARTERY: Normal.

RIGHT COMMON FEMORAL ARTERY: Normal.
RIGHT PROFUNDA FEMORIS ARTERY: Normal.
RIGHT SUPERFICIAL FEMORAL ARTERY: Normal.

RIGHT POPLITEAL ARTERY, RIGHT ANTERIOR TIBIAL ARTERY, RIGHT TIBIO-PERONEAL TRUNK, RIGHT COMMON PERONEAL ARTERY: There is early venous contamination leading to difficulty in evaluation. Right likely long-standing occlusion at level of distal popliteal artery with collateral vessels leading to reformation of single dominant artery in the lower leg 5 cm distally -common peroneal artery which distally gives rise to the posterior tibial artery.

Right Anterior tibial artery and dorsalis pedis arteries are not visualised.

LEFT COMMON ILIAC ARTERY: Slightly smaller calibre
LEFT EXTERNAL ILIAC ARTERY: Slightly smaller calibre
LEFT INTERNAL ILIAC ARTERY: Normal.

LEFT COMMON FEMORAL ARTERY: Slightly smaller calibre
LEFT PROFUNDA FEMORIS ARTERY: Normal.
LEFT SUPERFICIAL FEMORAL ARTERY: Slightly smaller calibre

LEFT POPLITEAL ARTERY: Normal.
LEFT ANTERIOR TIBIAL ARTERY: Hypoplastic
LEFT TIBIO-PERONEAL TRUNK, LEFT COMMON PERONEAL ARTERY: Single dominant artery in the leg which is likely the common peroneal artery
LEFT POSTERIOR TIBIAL ARTERY, LEFT DORSALIS PEDIS ARTERY: At the level of ankle, the common peroneal artery divides into dorsalis pedis and posterior tibial arteries.

ABDOMEN AND PELVIS: Few subcentimetre mesenteric nodes. Otherwise normal appearances

Name	: Dhananjay Mishra	852854
Age/Sex	: 25 years/ male	

Impression: Ununited compound comminuted fractures of tibia with external fixator and an intramedullary nail at distal shaft of tibia through the ankle joint stabilising the external fixator.

Extensive Superficial and deep soft tissue loss seen in the anterior part of the right distal leg and anterior compartment with blebs of air noted.

Possible collection with air fluid level anteromedially at the upper leg measuring 3 x 1.5 cm

Right likely long-standing occlusion at level of distal popliteal artery with collateral vessels leading to reformation of single dominant artery in the lower leg 5 cm distally -common peroneal artery which distally gives rise to the posterior tibial artery. Right Anterior tibial artery and dorsalis pedis arteries are not visualised.

On the left, Hypoplastic anterior tibial artery. Single dominant artery in the left lower leg which is likely the common peroneal artery. At the level of ankle, the common peroneal artery divides into dorsalis pedis and posterior tibial arteries.

Adv: Clinical Correlation.

DR. V.K. AGARWAL, MD

DR. RACHIT SIDANA; DNB

DR. RAVINDRA KUMAR BIND; MD

DR. KUSHAGRA AGRAWAL; MD

DR. UDBHAV MAHESHWARI; DMRD

DR. SEEMA PANDEY; MD

सेवा में;

भारामण सोशल वेल्फेयर फाउण्डेशन, (महोदय)
नई दिल्ली

विषय - अनुदान के संबंध में प्रार्थना पत्र,

महोदय,

अविनम निवेदन यह है कि मेरा नाम धनंजय कुमार मिश्र
सुत विजय कान्त मिश्र निवासी ग्रा. व. प्रो. बशीरपुर, तहसील
रानीगंज जिला- प्रतापगढ़ (उ०प्र०) का निवासी हूँ। जो कि
मेरे माता पिता दोनों विकलांग हैं पिता एक आँख से
माता बोल नहीं पाते हैं, पिता जी की उम्र लगभग 70 वर्ष
है। मेरी शक्ति दिनांक 4 मई 2017 को हुई, मेरा एक ही डेंट
दिनांक 25 मई 2017 को सड़क दुर्घटना में हो गया, उसमें
हमारा दाहिना पैर पूर्ण रूप से क्षतिग्रस्त हो गया। कई डॉ.
पैर काटने की सलाह दिया। परन्तु डॉ.का हॉस्पिटल इलाहाबाद
में डॉ. साहब पैर बचाने का प्रयास करने के पैर बचा सके। लगभग
दस ऑपरेशन अभी तक हुए हैं। अभी भी एक ऑपरेशन बाकी है।
पिता जी ने खेत बेच कर अभी तक इलाज कराये हैं अब हमारे
पास खेत भी नहीं है। इलाज में लगभग 25 लाख का खर्च हो गये
हैं। मैं आज दो वर्षोंबाद भी बेड पर ही हूँ। हम मुम्बई में रहकर
अपने परिवार का पालन पोषण करता था मेरी मासिक आय
7000 रूप्ये मात्र थी। सब लोग मुझ पर आत्मनिर्भर थे।

अतः आप से निवेदन है कि मेरे इलाज के लिए

कुछ सहायता प्रदान करने की कृपा करें। मैं भी चल फिर

सके जीवन भी हमारा सफल हो परिवार का पालन पोषण

कर सकूँ। आपका ^{सपरिणाम} अति आभारी रहूँगा।

आपका प्रार्थी

धनंजय कुमार मिश्र