



# NARAYAN SOCIAL WELFARE FOUNDATION (Regd.)

Head Office : 301, 3rd Floor, South Plaza-1, South Ext. Part-2, New Delhi 110049

Phone. No.: 011- 455 42 018 | Mobile No.:9999613753, 7827664266

Email:- info@narayanfoundation.org | www.narayanfoundation.org

## Beneficiary Registration Form

### Personal Details

First name: TINKI DEVI Last name: \_\_\_\_\_

Date of birth /age 40/28 Sex: M  F  Others

Qualification:- 10<sup>th</sup> Occupation Housewife Income per annum NA

Address: Vill- Shongra, Distt- LAKEHI SARAI, Bihar

### Family Details

Name	Relation	Date of Birth	Occupation	Income (yearly)
	Father	<u>NA</u>		
	Mother			
<u>Parmanand Singh</u>	Spouse	<u>95/13</u>	<u>labour</u>	<u>98000</u>
	Dependent	<u>NA</u>		

### Contact Details

Phone No: 91-8969542421 Email: NA

### Locality

Rural  Urban  Semiurban  Slum

Previous Consultations/Hospital Name:- Aiims new delhi

Age at which the Problem was Recognised 24/11/1990

### Past Diagnosis/diseases:-

Note/Remarks

Tic rapid AU sev dr  
hyposechic in xray smax 6mm on av

### Declaration:

I here by declare my authority to the management and staff of the foundation after being explained in details by the foundation authority in my own and understandable language about the above mentioned facility /procedure/treatments. I have also been explained that foundation will help and support. I will not hold the foundation responsible for any unfortunate incident.

Palce & Date: 22-06/2019 For Narayan Social Welfare Foundation

Parents/Guardians Name & Signature  
Yashraj Singh

APPROVED BY:  
NSWF

AUTHORISED SIGNATORY: / President  
By: \_\_\_\_\_

सेवा में

नारायण सोशल वेलफेयर फाउण्डेशन (महोदय)  
नई दिल्ली।

विषय अनुदान के संबंध में प्रश्ना पत्र।

महोदय, महोदया

सविनय निवेदन यह है मेरा नाम -

नाम - टिन्की देवी पति - परमानंद सिंह खना - एस

ग्रामनपा - धोंदसा खना - हलसी जिला - लखीसराय

बिहार का रहने वाला हूँ मुझे कांठीय लोको

(टाई) कि बीमारी पिछले छः महीना से है। मेरा इलाज

~~सफर~~ सफर जंग होस्पिटल नई दिल्ली में कर

रहा है। जो कि नारायण सोशल वेलफेयर फाउण्डेशन से हो रहा है।

आजीवन में एक साधारण कितान हूँ मेरा वार्षिक आय

पचास से साठ हजार रुपये मेरा परिवार में छः लोग

हैं। सब लोग मुझपर निर्भर हैं। मेरे इलाज के लिए

यह खर्च

उठाने में मैं अक्षम हूँ।

इसलिए आपसे सहायता आग्रह है कि मेरा इलाज के लिए  
साहाय्य प्रदान करें

अपका प्रार्थी

नाम - परमानंद सिंह

no - 8969542421



MRN00737837

HI

Date & Time : 12/06/2019 12:03 PM

Dept : Traage / Casualty

Name : Mrs. TINKI DEVI

Sex : Female

Father/Husband Name : PARMANAND SINGH

Address : VILL- GHONSA DIST- LAKHI SARAI BIHAR

Mobite No. : +91-8969542421 Unit : EH4

MLC : No SJH(NEB)

Address

Age : 40 Years

तारीख  
Date

उपचार/Treatment

12/6/19	Refused from AIIMS hospital
RSP - 91/89	for Cardio
PR - 81	chest pain for Cardio
SpO2 - 100%	DOB
RBS - 258 mg/dl	Severe AK / old wald
	Ashe vegetable
	PIE

DR. SHYAM SHARMA  
M.B.B.S., MD  
Senior Resident  
Dept. of Internal Medicine  
VMMC & Safdarjung Hospital  
New Delhi - 110029

Heart  
Counsel  
Cure

K/O Sevark | @ junction | old heated vegetable

of DOB - 11/12

- all day long

- all pedal edema


O/F

- EDM +ve in @ PS area  
and II of a

- BUN +ve, no hep b

Adv

@ Refer to ward for  
admission, Regis  
No beds. in ICU/  
In at present

  
**DR. RAHUL KUMAR**  
MBBS, MD (Medicine)  
DM-SR, Cardiology  
VMMC & Safdarjung Hospital  
New Delhi - 110029

ALL INDIA INSTITUTE OF MEDICAL SCIENCE, NEW DELHI  
DEPARTMENT OF CARDIOLOGY  
DISCHARGE SUMMARY

PATIENT DEMOGRAPHY DETAILS :

Patient ID: 104334001      Name: TINKI DEVI      Age: 40 Years, 3 Months, and 8 Days old.  
Sex: FEMALE      Mobile No: 6202137325  
Address: GHONGHASA LAKHISARAI, Bihar, INDIA  
CR NO: C-004917-19      CV NO: 606298/19/14      Ward: CT-3  
DOA: JUN 01, 2019      DOD: JUN 04, 2019

DIAGNOSIS:

SEVERE AR  
?OLD HEALED AORTIC VEGETATION  
NY II - DOE  
NS  
NORMAL LV FUNCTION

TREATMENT GIVEN IN HOSPITAL/ IN COURSE:

THROMBOLYSIS: NO

PATIENT WAS ADMITTED IN VIEW OF SUSPICION OF ENDOCARDITIS. PATIENT WAS EVALUATED AND ECHO SHOWED HYPERECHOIC 5MMX6MM MASS ATTACHED TO AV ?HEALED VEG. BLOOD CULTURES WERE SENT AND TEMPRATURE CHARTING WAS DONE. THERE WERE NO EPISODES OF FEVER DURING HOSPITAL STAY OR IN THE RECENT PAST. PATIENT DISCHARGED IN HEMODYNAMICALLY STABLE CONDITION.

TREATMENT ADVISED AT DISCHARGE:

- T. ENVAS 2.5MG BD - 9am - 9pm
- T. MET-XL 25MG OD - 9am
- T. RAB-D 1+0 OD
- TO REVIEW IN CT-3 WARD AFTER 3 DAYS FOR BLOOD C/S REPORT  
To collect ct angio report

FURTHER PLAN:

A

TO ATTEND CLINIC:

CARDIO OPD MON/WED/FRI  
AFTER: 1 WEEKS  
CONSULTANT FOR FOLLOW-UP:

INVESTIGATIONS:

Blood Group:

HEMOGRAM:

JUN 03, 2019

HB : 9.2  
TLC : 8990

ESR : 52  
Platelet : 3.23L

BIOCHEMICAL:

JUN 03, 2019

UREA : 20  
CREATININE : 0.7

CARDIAC ENZYME:

JUN 03, 2019

CRP : 4.32  
BLOOD C/S : AWAITED

CHEST XRAY:

CARDIOMEGALY

ECG:

NSR, NORMAL AXIS, NO SIG ST-T CHANGES

ECHO:

JUN 02, 2019

TRICUSPID AV, SEV AR  
HYPERECHOIC MASS 5MMX6MM ON AV ?HEALED VEG  
NORMAL LV FUNCTION  
LV 63/47  
MOD MR, NORMAL MV LEAFLETS

CONSULTANT: DR RAKESH YADAV

SENIOR RESIDENT:

*[Handwritten Signature]*



### Coronary Angiography Report

Name : Mrs. tinki

Cathlab No. 2463/2019

Angio No. 2463/2019

MRD No. : 49805/2019

Mobile No.

Date of Procedure 19-Jun-19

Age 40 Years

Sex Female

#### Precath Diagnosis

RHD

#### Procedural Details

Access Right Radial Wire 0.035" Contrast Nonionic Catheters Tiger, Make cordis, Curve 3

Others

Aortic Pressure 110/70 mmHg

#### Coronary Artery Profile

##### Left main coronary artery

Left Main artery : Normal

##### Left anterior descending artery (LAD)

LAD : Normal

##### Left circumflex artery (LCX)

LCX : Normal

##### Right coronary artery (RCA)

RCA : Normal

Gensini Score

#### Associated Lesions

#### Complications

No In-lab complications

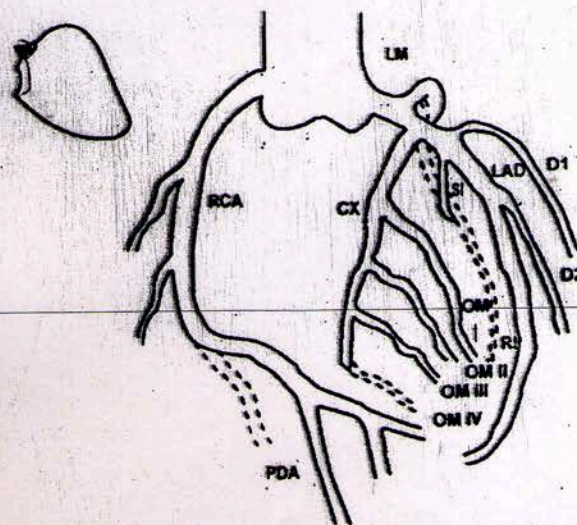
#### Diagnosis

Final Diagnosis Normal coronary arteries

#### Advice

Medical management

#### Remarks



GOVT. OF INDIA  
 VARDHMAN MAHAVIR MEDICAL COLLEGE & SAFDARJUNG HOSPITAL  
 DEPARTMENT OF CARDIOLOGY  
 NEW DELHI - 110029  
**DR. SANDEEP BANSAL**

Head of Department of Cardiology

**UNIT-1**

**Dr. Sandeep Bansal**  
 Consultant & Professor  
 Head of Unit

**Dr. Preeti Gupta**  
**Dr. Anunay Gupta**

MRD NO. 51896

DISCHARGE DIAGNOSIS: RHD / sev MR / sev AR / old calcified vegetation / (aortic junction)  
 PTCA - STENT DETAIL ADHF (Improved) / (sev. Anemia)

PATIENT NAME TILKI AGE 40 SEX F (M/F)

**RISK FACTORS - I**

WARD/BED NO. 34/15  
 ADMISSION ON 22/6/2019  
 DISCHARGE ON 25/6/2019

- \* DIABETES MELLITUS \_\_\_\_\_ (Y/N)
- \* HYPERTENSION \_\_\_\_\_ (Y/N)
- \* SMOKER/TOBACCO USE \_\_\_\_\_ (Y/N)
- \* PAST CAD \_\_\_\_\_ (Y/N)
- \* DYSLIPIDEMIA \_\_\_\_\_ (Y/N)
- \* FAMILY HISTORY \_\_\_\_\_ (Y/N)

ANGIO REPORT/NO. CAD: (a) coronary

HOSPITAL COURSE: \_\_\_\_\_

**MAIN INVESTIGATIONS (ECG/ECHO)**

Hb 8.3 2D-Echo  
71 ± 11200 (Report attached)  
PLT ± 1.27  
B.U ± 46  
Su ± 1.3  
Na<sup>+</sup> ± 136  
K<sup>+</sup> ± 3.8  
VM ± -ve

**TREATMENT ADVISED AT DISCHARGE**

DIET & EFFORT AS EXPLAINED

1. T. Dylor plus 120/50 100
2. T. Flecainide 250 00
3. T. Ramipril 2.5 4 130
4. T. Pantec 100 4 130
5. \_\_\_\_\_ x 15 day
6. Folic
7. \_\_\_\_\_
8. \_\_\_\_\_

FOR FOLLOW UP PATIENT TO COME ON TUESDAY/FRIDAY AT 9 AM AFTER 2 WEEKS IN CARDIOLOGY OPD.

**NOTE: PLEASE LAMINATE THE DISCHARGE SUMMARY**

*Saby*  
**SR RESIDENT**  
 DM-3 (Cardiology)  
 VMMC & Safdarjung Hospital  
 New Delhi - 110029

**SPECIALIST**



ID: 18

Name:

*1/2/21*

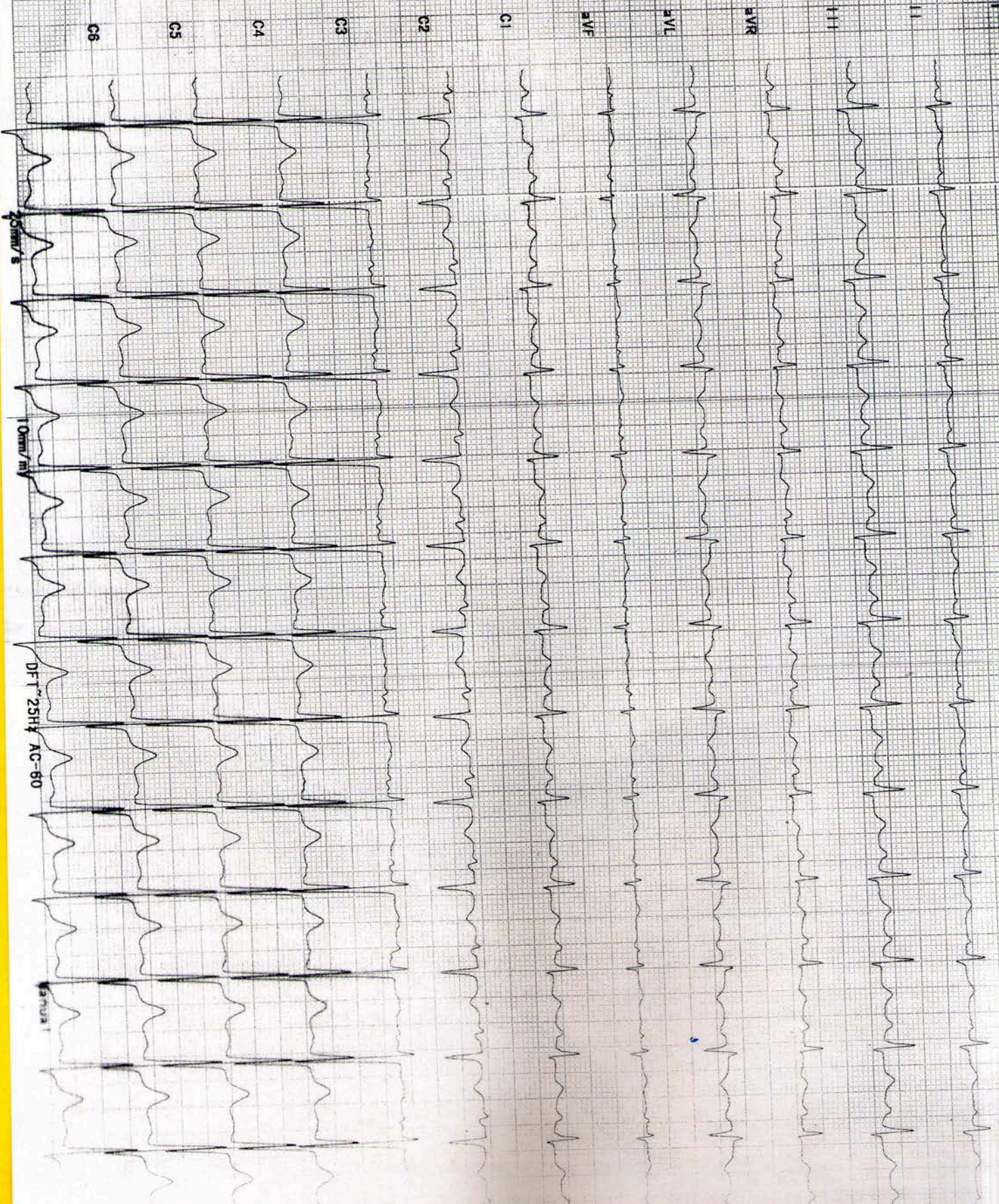
Age:

*P*

Gender:

HR: 90

2015 08 21 09:30



1mV

aVF

aVL

aVR

III

II

C1

C2

C3

C4

C5

C6

10mm/s

10mm/m

DFT 25Hz AC-60

STUR 1

Report **DEVI, TINKI CR CT - Cardiac 6/4/2019 CT**

Department of Neuroimaging & Interventional Neuroradiology

Cardio-Thoracic & Neuro-Sciences Centre

AIIMS, Ansari Nagar, New Delhi-110029

-----  
Patient Name : Tinki Devi  
Patient ID : 4966419  
Age / Sex : 27/02/1979 / W  
Procedure : CR CT - Cardiac  
Exam Date : 04/06/2019  
Reported By : Dr Sanjeev Kumar  
-----

## INVESTIGATION REPORT

### CT CORONARY ANGIOGRAPHY

#### Findings:

Dominance: Right

LM: Normal origin & course. No significant disease.

LAD: Normal origin & course. No significant disease.

Diagonals: Normal origin & course. No significant disease.

LCx: Normal origin & course. No significant disease.

Obtuse Marginals: Normal course. No significant disease.

RCA: Normal origin & course. No significant disease.

PDA: No significant disease. PLV: No significant disease.

Cardiac valves: mildly thickened aortic leaflets with focus of calcification

Cardiac chambers: cardiomegaly with biventricular dilatation and mild systolic dysfunction. Ascending aorta not dilated.

Visualized lung fields and mediastinum: Interlobular septal thickening in both lungs. Moderate right pleural effusion. mild pericardial effusion

#### Impression:

No obstructive CAD.

LV systolic dysfunction, right pleural and mild pericardial effusion.

Cardiac Radiologist: Dr.Mumun Sinha / Dr Sanjeev Kumar

हृदय रोग विज्ञान विभाग  
सफदरजंग अस्पताल, नई दिल्ली-29  
**DEPARTMENT OF CARDIOLOGY**  
**SAFDARJUNG HOSPITAL, NEW DELHI-29**

इकोकार्डियोग्राम रिपोर्ट  
**ECHOCARDIOGRAM REPORT**

5748/19  
13 JUN 2019

13 JUN 2019

NAME Timbi AGE 45 SEX M/F DATE  
ECHO NO \_\_\_\_\_ OPD Reg. No. \_\_\_\_\_ MRD No. \_\_\_\_\_ VCR TAPE No. \_\_\_\_\_  
HEIGHT \_\_\_\_\_ cms WEIGHT \_\_\_\_\_ kg BSA \_\_\_\_\_ m<sup>2</sup> Ref Physician \_\_\_\_\_  
Referring Diagnosis \_\_\_\_\_ Done by Dr. \_\_\_\_\_ Checked by Dr. \_\_\_\_\_  
Quality of Imaging \_\_\_\_\_ Poor/Adequate/Good

Measurements

Normal Values

Normal Values

Aorta	<u>28</u>	(21-22 mm/m <sup>2</sup> )	LA es.	<u>45</u>	(21-22 mm/m <sup>2</sup> )
Lves	<u>4.6</u>	(16-19 mm/m <sup>2</sup> )	LV ed.	<u>68</u>	(19-32 mm/m <sup>2</sup> )
IVS ed.	<u>9</u>	(6-10 mm)	PW (LV) ed.	<u>8</u>	(7-11 mm)
RV ed.		(4-14 mm/m <sup>2</sup> )	RV Anterior wall.		(upto 5 mm)
EF	<u>60-65%</u>	(82-80%)			
IVS Motion		(Normal/Flat/Paradoxical)			
IAS					

CHAMBERS

LV	Normal/Enlarged/Clear/Thrombus/Hypertrophy
	Contraction Normal/Reduced
LA	Normal/Enlarged/Clear/Thrombus
RA	Normal/Enlarged/Clear/Thrombus
RV	Normal/Enlarged/Clear/Thrombus

*Normal*

PERICARDIUM

Normal/Thickening/Calcification/Enlarged

MITRAL VALVE

Morphology AML Normal/Thickening/Calcification/Flutter/Vegetation/Prolapse/SAM/Doming  
PML Normal/Thickening/Calcification/Prolapse/Paradoxical Motion/Fixed  
Subaicular Deformity Present/Absent

Doppler Normal/Abnormal Score \_\_\_\_\_  
Mitral Stenosis Present/Absent RR Interval \_\_\_\_\_ msec  
EDG \_\_\_\_\_ mmHg MDG \_\_\_\_\_ mmHg MVA \_\_\_\_\_ cm<sup>2</sup>  
Mitral Regurgitation Absent/Trivial/Mild/Moderate/Severe

*Everted ml*

TRICUSPID VALVE

Morphology Normal/Atresia/Thickening/Calcification/Prolapse/Vegetation/Doming  
Doppler Normal/Abnormal  
Tricuspid Stenosis Present/Absent RR Interval \_\_\_\_\_ msec  
EDG \_\_\_\_\_ mmHg MDG \_\_\_\_\_ mmHg  
Tricuspid Regurgitation Absent/Trivial/Mild/Moderate/Severe Fragmented Signals  
Velocity \_\_\_\_\_ m/sec Pred. RSVP=RAP+ \_\_\_\_\_ mmHg

*44*

**PULMONARY VALVE**

Morphology Doppler Normal/Atresia/Thickening//Doming/Vegetation  
 Normal/Abnormal  
 Pulmonary Stenosis Present/Absent Level  
 PSG.....mmHg Pulmonary annulus.....mm  
 Pulmonary Regurgitation Present/Absent  
 Early diastolia Gradient End diastolic gradient ..mmHg

**AORTIC VALVE**

Morphology Doppler Normal/Thickening/Calcification/R Restricted opening/Flutter/Vegetation No. of cusps 1/2/3/4  
 Normal/Abnormal  
 Aortic Stenosis Present/Absent Level  
 PSG.....mmHg Aortic annulus 20.....mm  
 Aortic Regurgitation Absent/Trivial/Mild/Moderate/Severe

**FINAL IMPRESSION**

TEE

AMI Proximal  
 Mod Eccentric MR  
 Mild

Severe TR (PUSP + RAP)  
 Mod

Sev. AR

8 x 4 mm veg on

Ao V - Mobile & Hinged

4 x 3 mm (on left leaflet) **DRCC**

Ao v - Mobile & Hinged.

Tricuspid Annulus 51mm

Ⓧ LV function

**DIAGNOSIS**

22/6/19 ~~16/07/19~~  
 consultant echo.

**Dr. Anunay GUPTA**  
 MD (Medicine) AIIMS  
 DM (Cardiology) AIIMS  
 Assistant Professor  
 Department of Cardiology  
 VMMC & Safdarjung Hospital  
 New Delhi-110029

Imp - Sev AR /  
 ? Hinged IL (2 veg.) /  
 mod Eccentric MR /

Ⓧ LV function

Resident

Consultant

22/6/19

TTE by Dr Anunay Gupta  
 - mild. MR, sev AR, Mod TR  
 hinged veg on left coronar  
 cusp of Ao V.

# LAMA Summary

FDA

सफदरजंग अस्पताल, नई दिल्ली-110029  
SAFDARJUNG HOSPITAL, NEW DELHI-110029

## विवरण-पत्र CASE-SHEET

संख्या No.	नाम Name	पुरुष/स्त्री Sex	जाति Caste	आयु Age
	Timki Devi	40/F		
	व्यवसाय Occupation	पता Address		
	प्रवेशन तिथि Date of admission			
वर्ष Year	उन्मोचन तिथि Date of discharge		आहार Diet	
	रोग Disease			
	परिणाम Result			

Severe AR & calcified vegetat<sup>n</sup>.  
 Severe AR plw intermittent  
 chest pain, palpitation & 2 days, SOB an  
 exertion & 1 month, N/H/O fever, ↓VO,  
 T2DM, HTN, TB, Atherosclerosis, seizures

BP - 136/54.  
 O/E : conscious oriented  
 CVS - S3 ⊕, Diastolic murmur ⊕  
 RLs - B/L A2 ⊕ clear.  
 P/A - SOFT NT  
 CNS - WNL

Regimen :  
 iny Monocet  
 iny Vancosmycin  
 iny Rantac  
 iny emser  
 124 NS